

MINISTRY OF EDUCATION AND SCIENCE OF UKRAINE  
TARAS SHEVCHENKO NATIONAL UNIVERSITY OF KYIV

# HISTOLOGY, CYTOLOGY, EMBRYOLOGY

Workbook for foreign students of specialization "Medicine"

## Part 2. General Histology

Видавничо-поліграфічний центр  
"Київський університет"  
Версія не для друку

Compliers:  
I. V. Byelinska, O. V. Lynchak, V. G. Khoperia,  
A. S. Pustovalov, I. M. Vareniuk, V. Ye. Kalynovskyi, M. E. Dzerzhynsky

Reviewers:  
Dr. Hab., Prof. M. Yu. Makarchuk,  
Dr. Hab., Prof. S. V. Demydov

*Approved by Academic Council  
of Educational Scientific Center "Institute of Biology and Medicine"  
(protocol № 5 from November 23, 2020)*

Histology, Cytology, Embryology. Workbook for foreign students of specialization "Medicine". Part 2. General Histology / compliers : I. V. Byelinska, O. V. Lynchak, V. G. Khoperia et al. – Publishing and Polygraphic Center "Kyiv University", 2021. – 27 p.

Навчальне видання

## ГІСТОЛОГІЯ, ЦИТОЛОГІЯ ТА ЕМБРІОЛОГІЯ

Робочий зошит для іноземних студентів спеціалізації "Медицина"

Частина 2. Загальна гістологія

(Англійською мовою)

Упорядники:

**Бєлінська** Ірина Василівна, **Линчак** Оксана Валеріївна, **Хоперія** Вікторія Геннадіївна, **Пустовалов** Андрій Сергійович,  
**Варенюк** Ігор Миколайович, **Калиновський** Віталій Євгенійович, **Дзержинський** Микола Едуардович




Формат 60x84<sup>1/8</sup>. Ум. друк. арк. 3,3. Наклад 300. Зам. №  
Гарнітура Times New Roman. Папір офсетний. Друк офсетний. Вид. № Б6.  
Підписано до друку

Видавець і виготовлювач  
ВПЦ "Київський університет"

Б-р Тараса Шевченка, 14, м. Київ, 01601, Україна  
☎ (38044) 239 32 22; (38044) 239 31 72; тел./факс (38044) 239 31 28  
e-mail: vpc\_div.chief@univ.net.ua; redaktor@univ.net.ua  
http: vpc.univ.kiev.ua  
Свідоцтво суб'єкта видавничої справи ДК № 1103 від 31.10.02

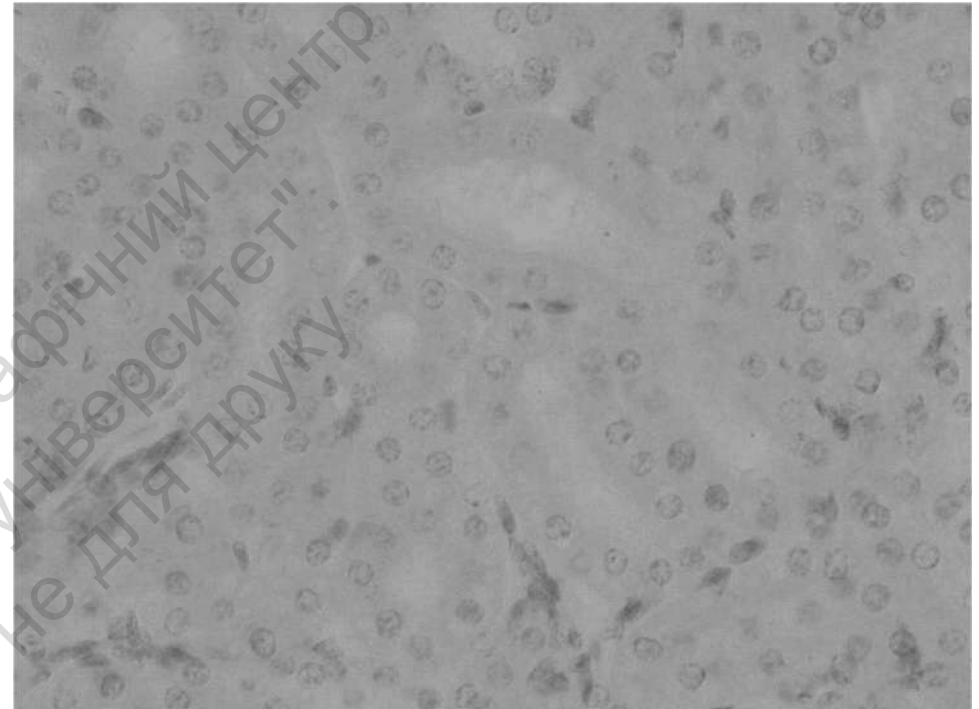
# Topic 1

## COVERING (LINING) EPITHELIUM



**Specimen 1. Simple squamous epithelium (flat cells), mesothelium (silver stain, ×400):**

1) plasma membrane; 2) cytoplasm; 3) nucleus.

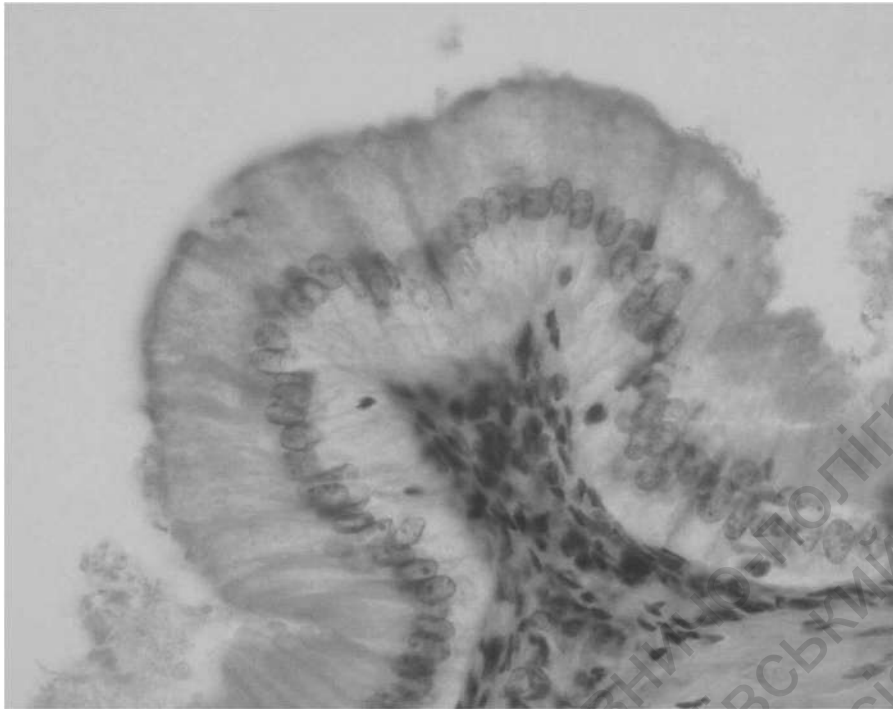


**Specimen 2. Simple cuboidal epithelium, kidney (hematoxylin and eosin stain, ×400):**

1) cuboidal epithelial cell;  
2) plasma membrane of epithelial cell;  
3) nucleus of epithelial cell; 4) cytoplasm of epithelial cell.

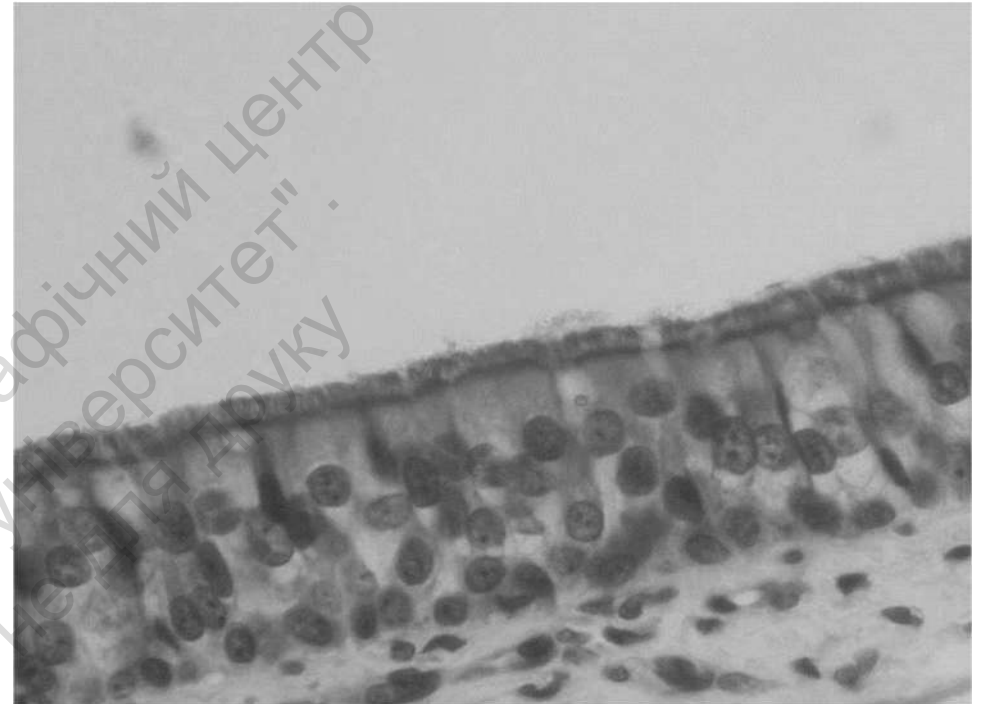
# Topic 1

## COVERING (LINING) EPITHELIUM



**Specimen 3. Simple columnar epithelium**  
(hematoxylin and eosin stain,  $\times 400$ ):

- 1) columnar epithelial cell;
- 2) plasma membrane of epithelial cell;
- 3) nucleus of epithelial cell;
- 4) cytoplasm of epithelial cell.

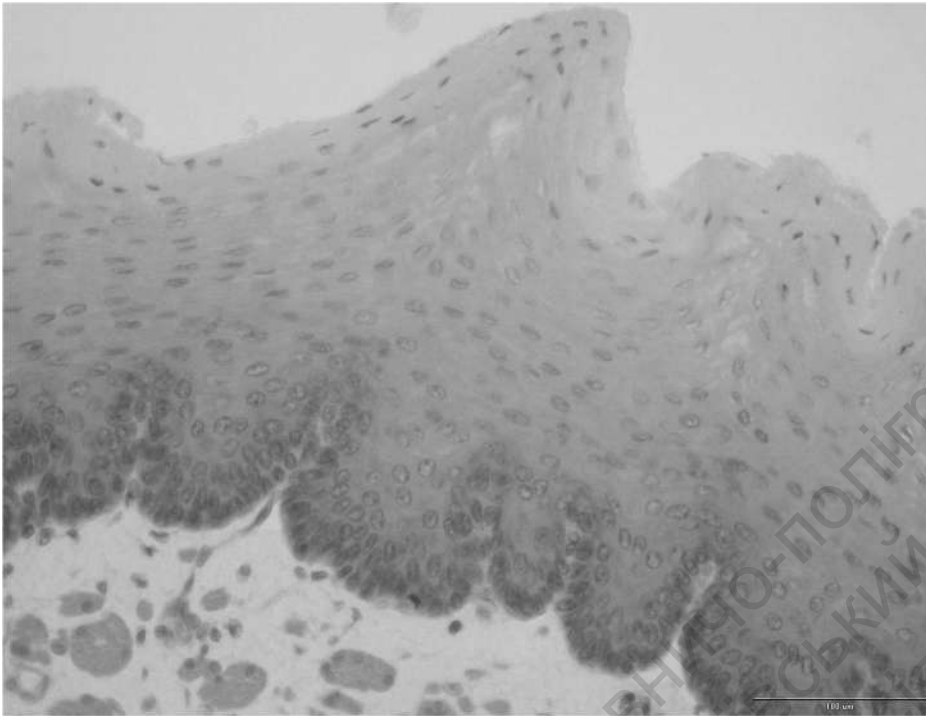


**Specimen 4. Pseudostratified columnar ciliated epithelium**  
(hematoxylin and eosin stain,  $\times 400$ ):

- 1) ciliar epithelial cell;
- 2) cilia;
- 3) basal body;
- 4) basal membrane (basal lamina);
- 5) basal cell;
- 6) Goblet cell.

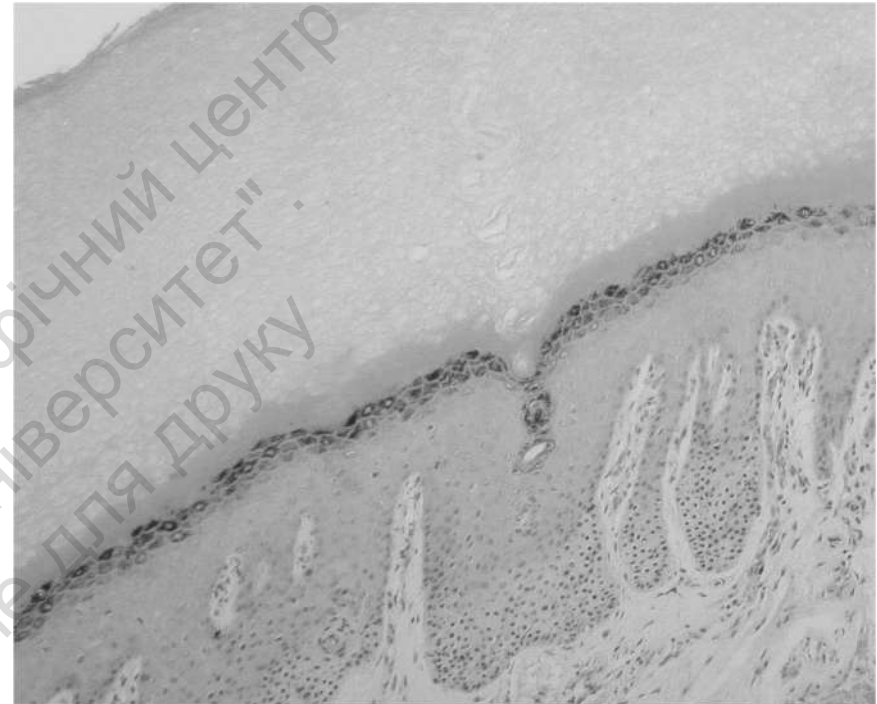# Topic 1

## COVERING (LINING) EPITHELIUM



**Specimen 5. Stratified non-keratinized squamous epithelium, amphibian skin (hematoxylin and eosin stain,  $\times 400$ ):**

- 1) basal layer (low columnar cells);
- 2) basal membrane;
- 3) medium layer (polygonal cells);
- 4) external layer (flat cells);
- 5) cells of squamous epithelium.

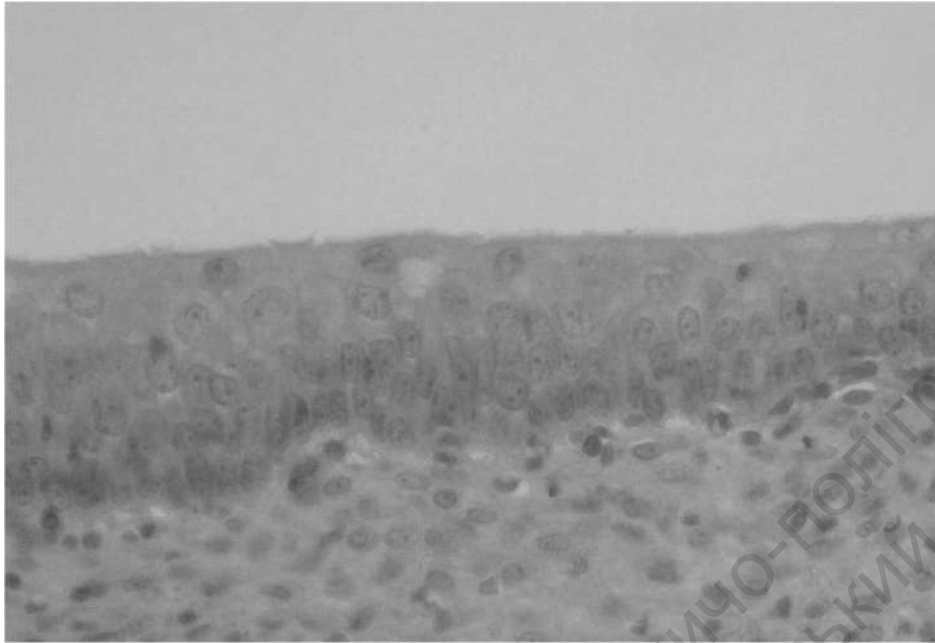


**Specimen 6. Stratified squamous keratinized epithelium, skin of finger (hematoxylin and eosin stain,  $\times 400$ ):**

- 1) basal layer (low columnar cells);
- 2) stratum spinosum layer (stellate cells);
- 3) granular layer (flat, rhomb-shaped cells);
- 4) clear layer (corneum lucidum);
- 5) horny layer (died cells).

# Topic 1

## COVERING (LINING) EPITHELIUM



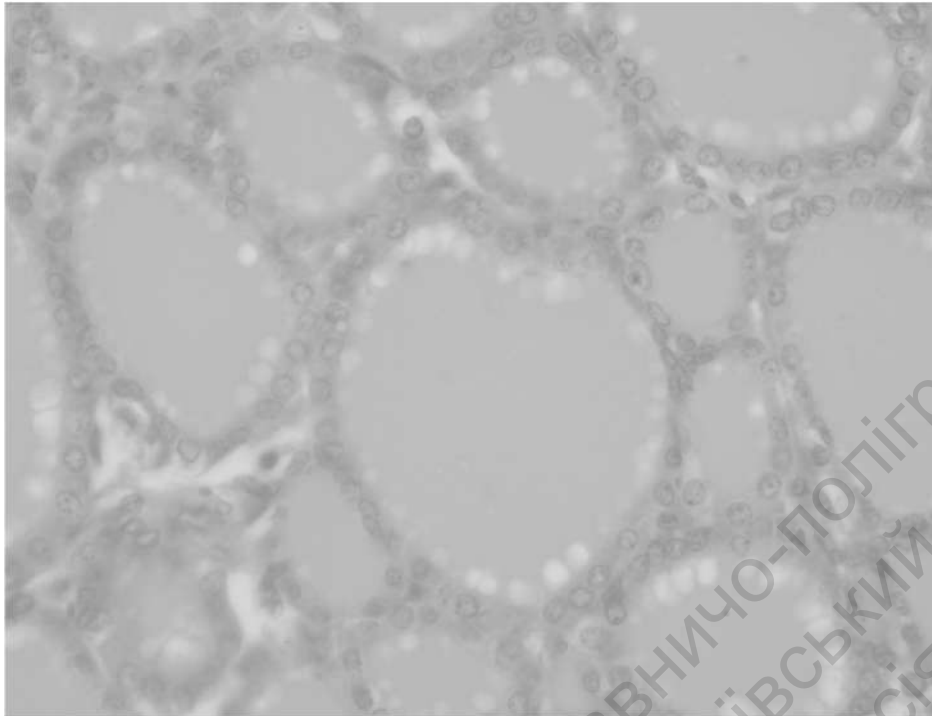
**Specimen 7. Transitional epithelium, urinary bladder  
(hematoxylin and eosin stain, ×400):**

- 1) basal layer (low columnar cells);
- 2) basal membrane;
- 3) medium layer pear-shaped cells);
- 4) external layer (flat cells);
- 5) cells of squamous epithelium.

Teacher's signature \_\_\_\_\_

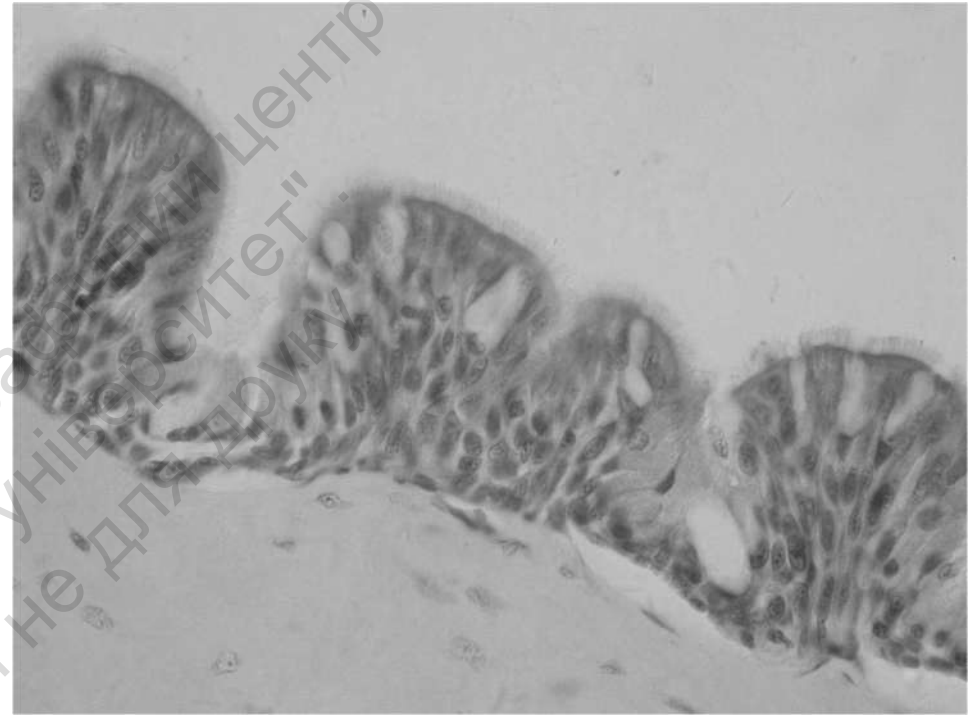
## Topic 2

# GLANDULAR EPITHELIUM



**Specimen 1. Thyroid gland, endocrine gland  
(hematoxylin and eosin stain, ×400):**

- 1) glandular cuboidal epithelial cell; 2) basal membrane;
- 3) plasma membrane of epithelial cell;
- 4) nucleus of epithelial cell; 5) cytoplasm of epithelial cell;
- 6) secreted product.

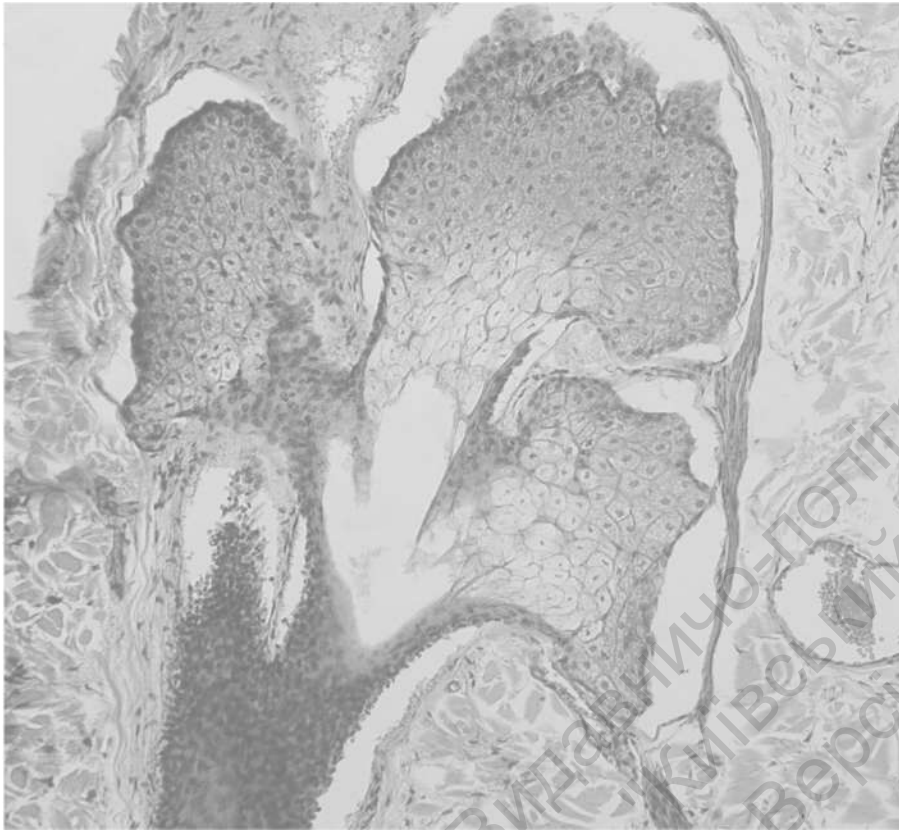


**Specimen 2. Unicellular gland (scattered cells) – Goblet cells  
in pseudostratified ciliated epithelium, merocrine type of secretion  
(hematoxylin and eosin stain, ×400):**

- 1) Goblet cell; 2) nucleus of Goblet cell; 3) cytoplasm of Goblet cell;
- 4) cells of ciliated columnar epithelium; 5) basal membrane (lamina).

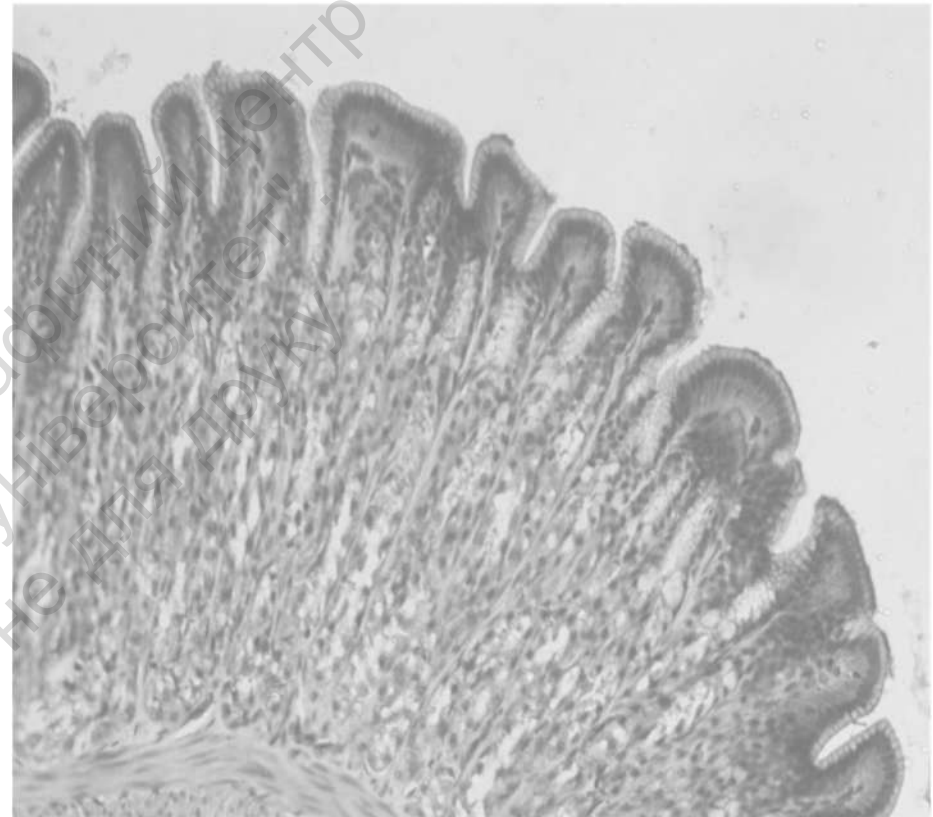
## Topic 2

# GLANDULAR EPITHELIUM



**Specimen 3. Simple branched alveolar (acinar) gland, sebaceous gland of skin, holocrine type of secretion (hematoxylin and eosin stain,  $\times 150$ ):**

- 1) acinus of gland, 2) duct of gland, 3) glandular epithelial cell;
- 4) basal membrane; 5) plasma membrane of glandular epithelial cell;
- 6) nucleus of epithelial cell; 7) cytoplasm of epithelial cell;
- 8) secreted product.

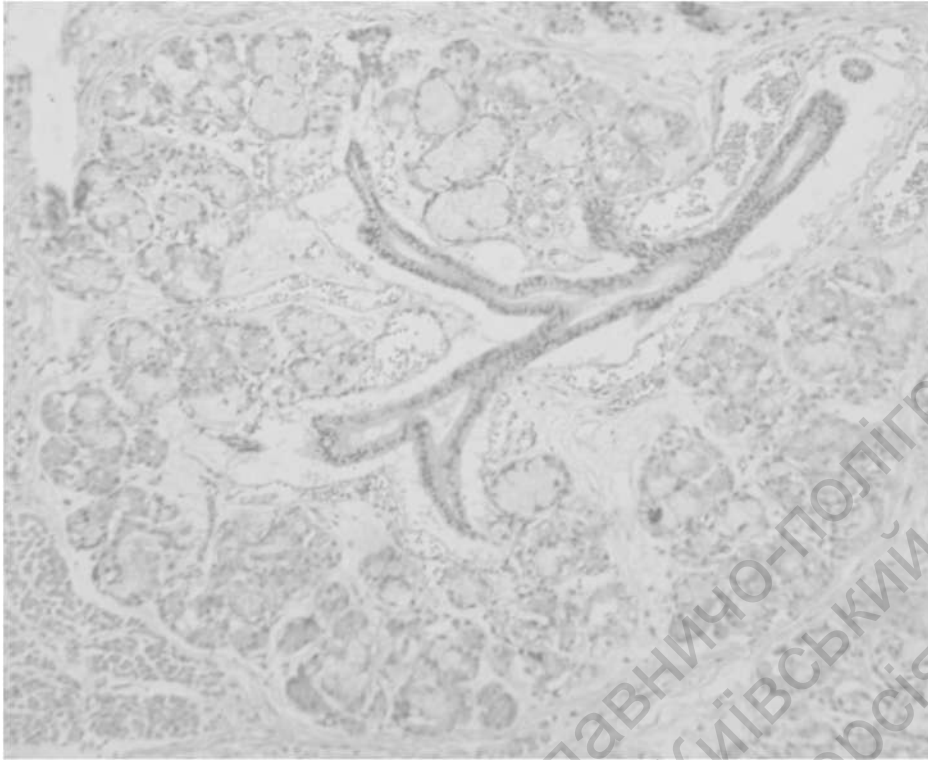

**Specimen 4. Simple branched tubular gland, fundus of stomach (hematoxylin and eosin stain,  $\times 150$ ):**

- 1) glandular epithelial cell; 2) basal membrane;
- 3) plasma membrane of glandular epithelial cell;
- 4) nucleus of epithelial cell; 5) cytoplasm of epithelial cell.

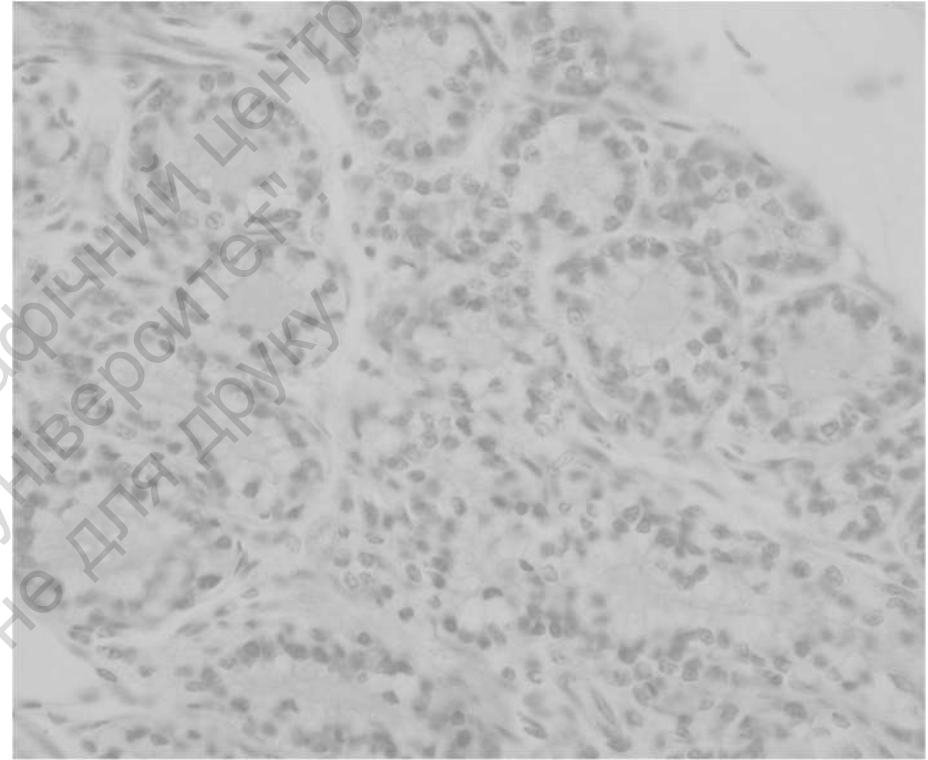
## Topic 2

# GLANDULAR EPITHELIUM



**Specimen 5. Compound alveolar gland, lip of human fetus  
(hematoxylin and eosin stain, ×150):**

- 1) glandular epithelial cell;
- 2) basal membrane;
- 3) plasma membrane of glandular epithelial cell;
- 4) nucleus of epithelial cell;
- 5) cytoplasm of epithelial cell;
- 6) secreted product.



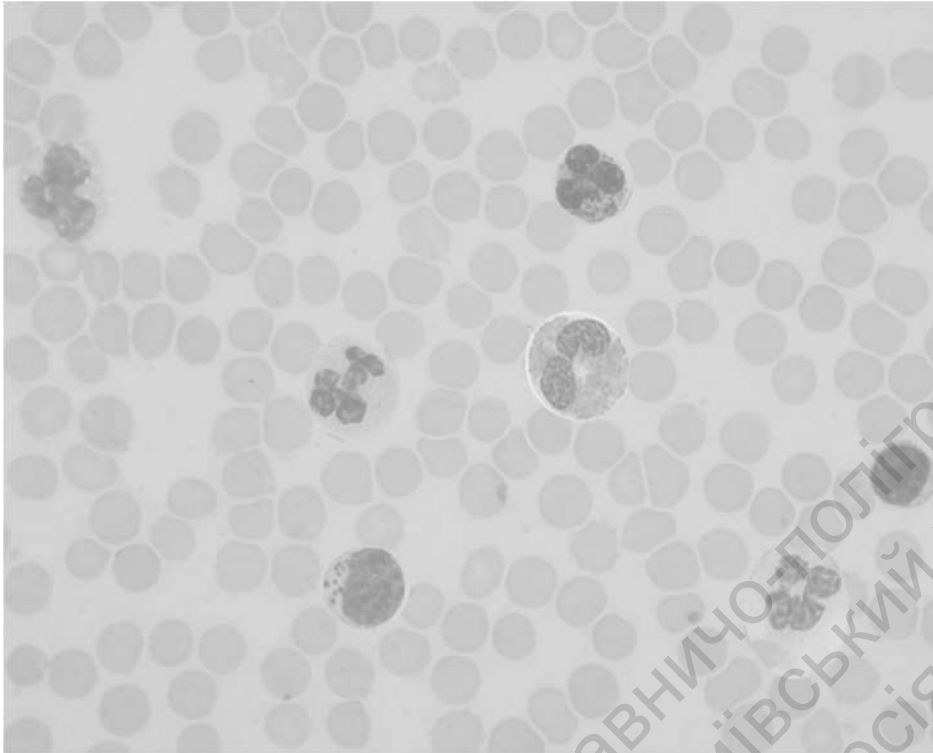
**Specimen 6. Mammary gland, apocrine type of secretion  
(hematoxylin and eosin stain, ×400):**

- 1) glandular cuboidal epithelial cell;
- 2) basal membrane;
- 3) plasma membrane of epithelial cell;
- 4) nucleus of epithelial cell;
- 5) cytoplasm of epithelial cell;
- 6) secreted product.

**Teacher's signature** \_\_\_\_\_

### Topic 3

## BLOOD AND LYMPH



**Specimen 1. Blood smear (Romanowsky-Giemsa stain, ×1000):**

- 1) neutrophilic granulocyte;
- 2) basophilic granulocyte;
- 3) eosinophilic granulocyte;
- 4) lymphocyte;
- 5) large granular lymphocyte;
- 6) monocyte;
- 7) erythrocyte.

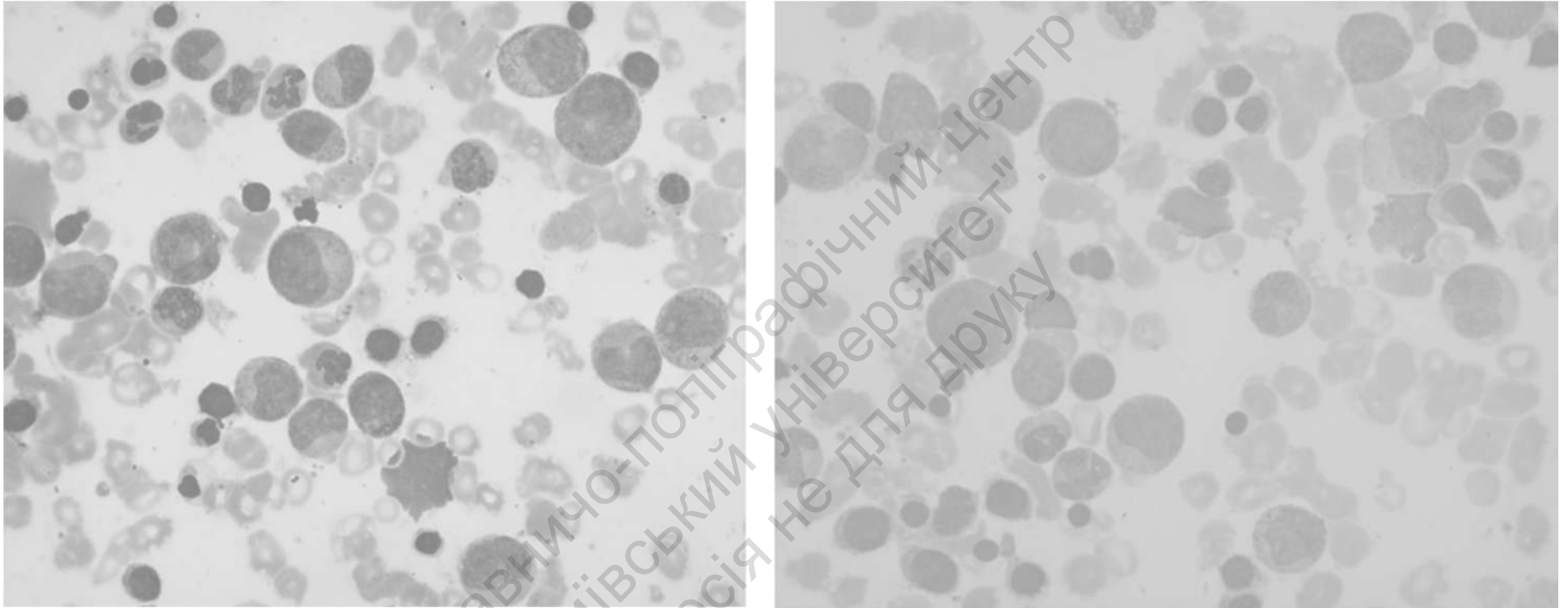


**Specimen 2. Blood smear (brilliant cresyl blue stain, ×1000):**

- 1) erythrocyte;
- 2) reticulocyte.

Teacher's signature \_\_\_\_\_

## Topic 4 HEMATOPOIESIS



**Specimen 1. Bone marrow smear (Romanowsky-Giemsa stain,  $\times 1000$ ):**

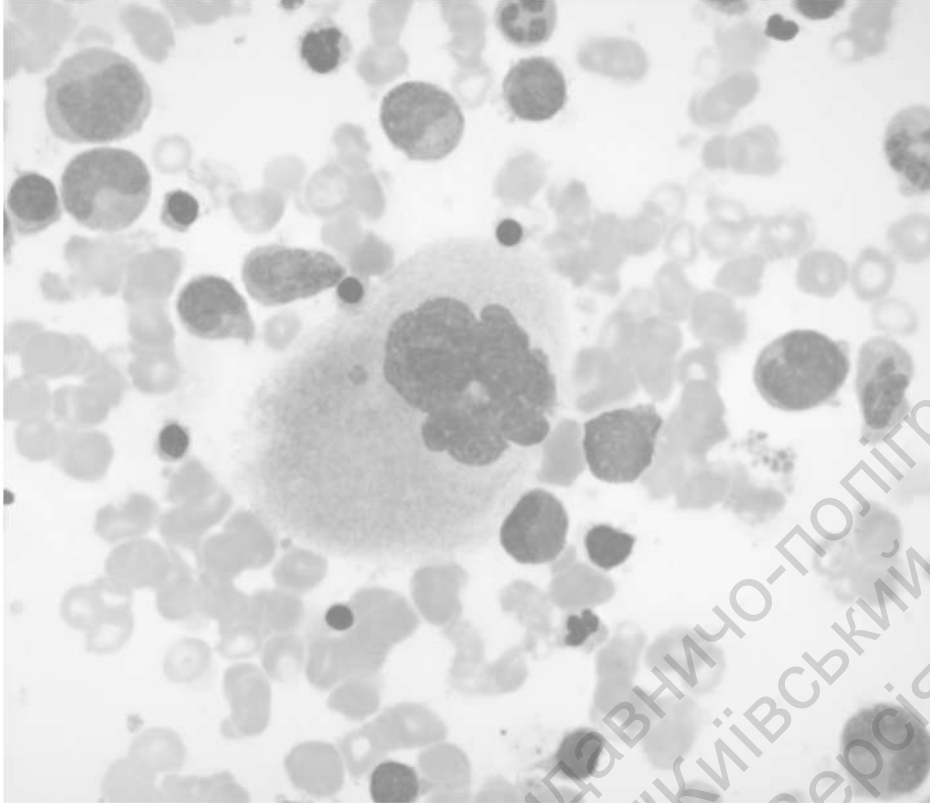
### **Myelopoiesis**

- 1) myeloblast;
- 2) promyelocyte;
- 3) neutrophilic myelocyte;
- 4) eosinophilic myelocyte;
- 5) neutrophilic metamyelocyte;
- 6) band neutrophil;
- 7) segment neutrophil;
- 8) monocyte;
- 7) lymphocyte.

### **Erythropoiesis**

- 1) erythroblast;
- 2) basophilic normoblast;
- 3) polychromatophilic normoblast;
- 4) oxyphilic normoblast;
- 5) erythrocyte.

## Topic 4 HEMATOPOIESIS

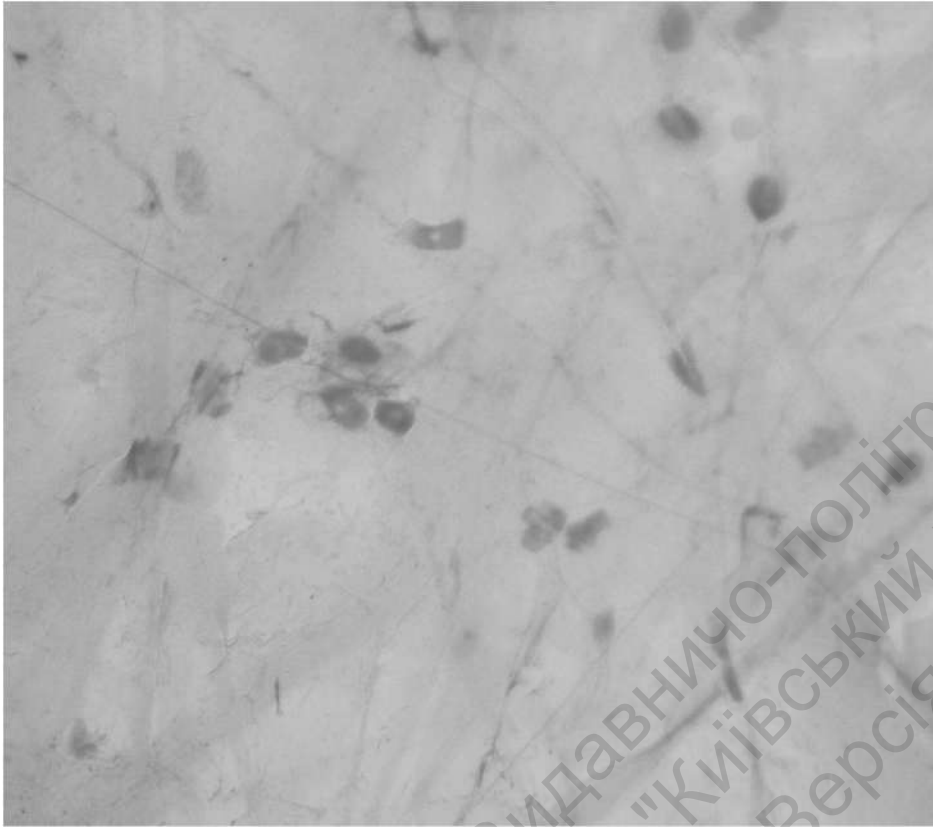


**Specimen 1. Bone marrow smear**  
**(Romanowsky-Giemsa stain,  $\times 1000$ ): Megakaryocytogenesis**  
1) megakaryocyte; 2) polyploid nucleus; 3) cytoplasm.

Teacher's signature \_\_\_\_\_

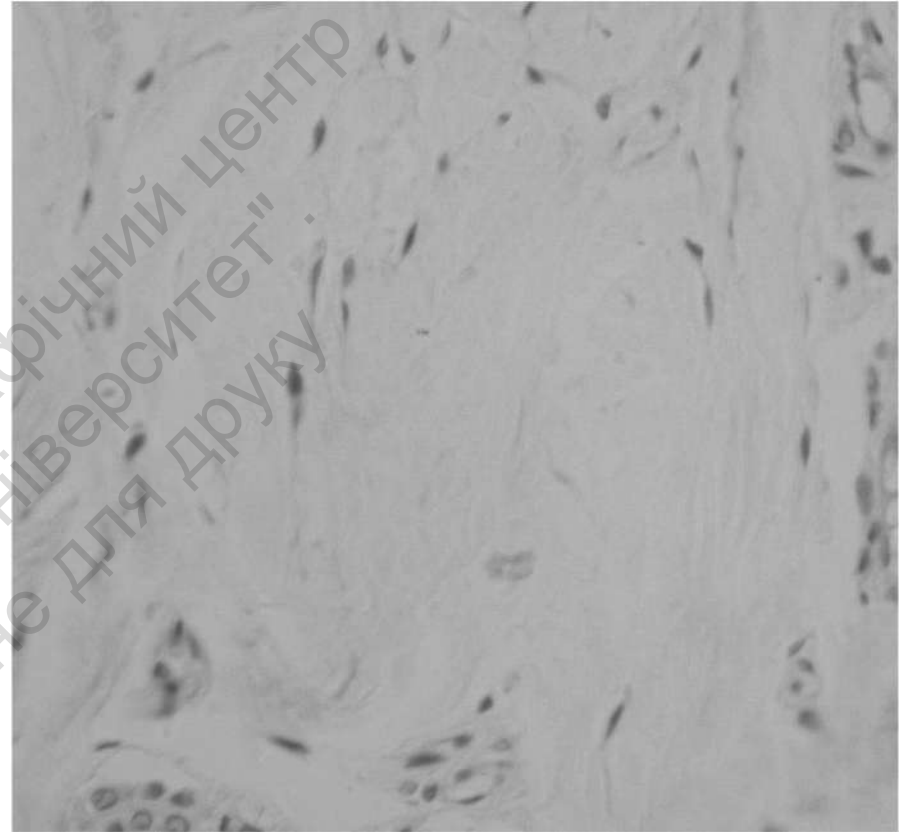
## Topic 5

# PROPER CONNECTIVE TISSUE



**Specimen 1. Loose connective tissue**  
(iron hematoxylin stain,  $\times 400$ ):

- 1) fibroblast;
- 2) macrophage;
- 3) lymphocyte;
- 4) collagen fiber;
- 5) elastic fiber.




**Specimen 2. Dense irregular connective tissue**  
(hematoxylin and eosin stain,  $\times 400$ ):

- 1) fibroblast;
- 2) collagen fiber.

## Topic 5

### PROPER CONNECTIVE TISSUE



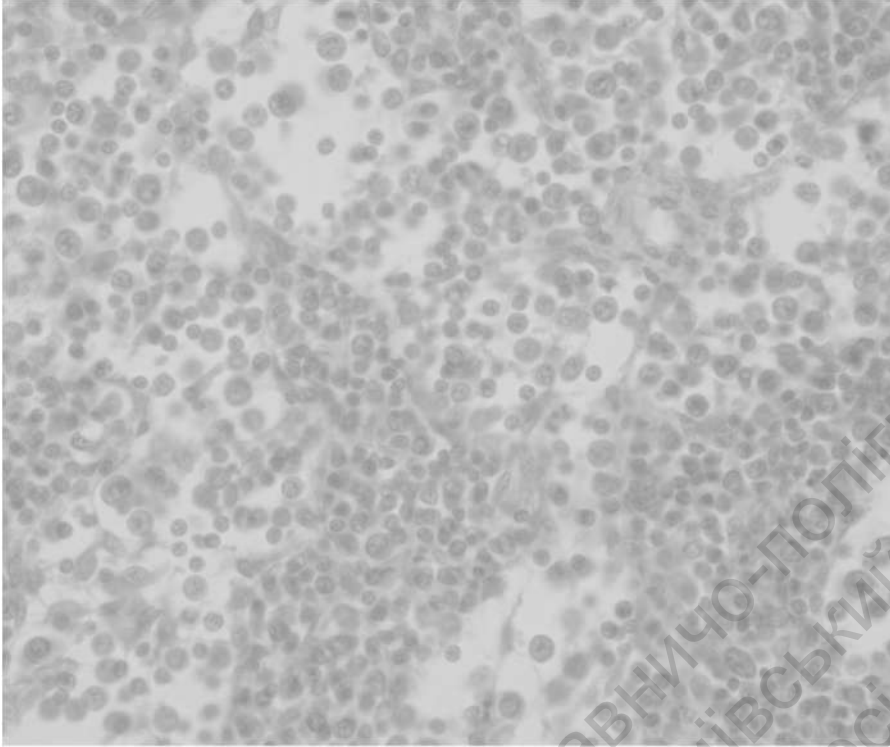
**Specimen 3. Dense regular connective tissue, tendon  
(hematoxylin and eosin stain, ×400):**

1) fibroblast; 2) collagen fiber; 3) peritendineum; 4) endotendineum

Teacher's signature \_\_\_\_\_

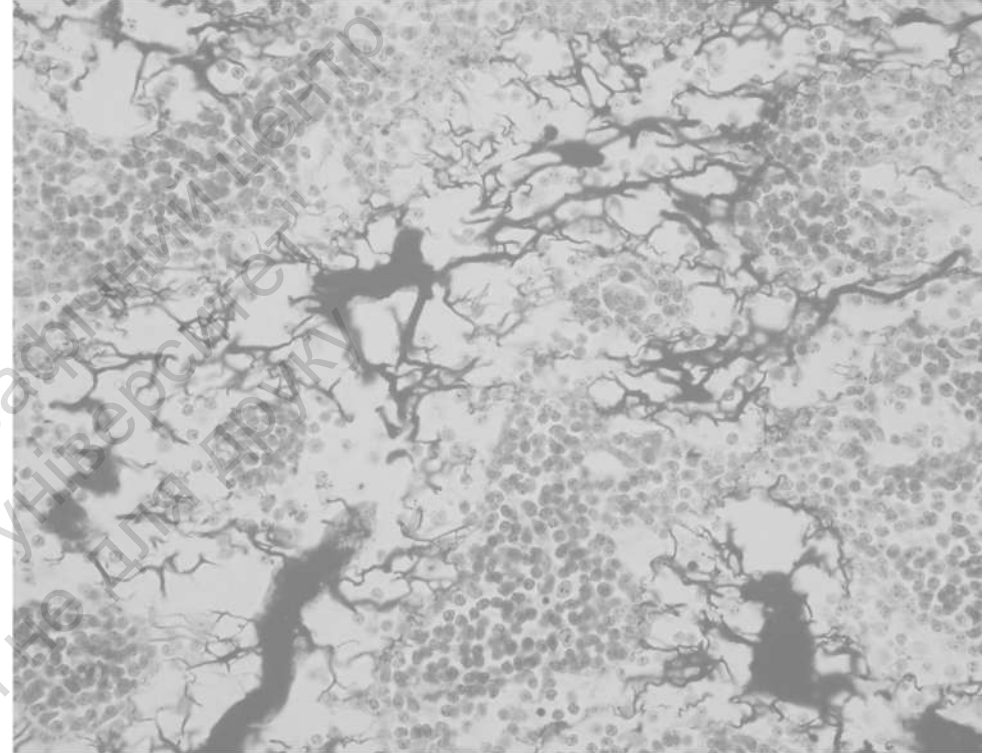
## Topic 6

# SPECIALIZED CONNECTIVE TISSUE



**Specimen 1. Reticular tissue**  
(hematoxylin and eosin stain,  $\times 400$ ):

1) reticular cell; 2) macrophage; 3) lymphocyte.

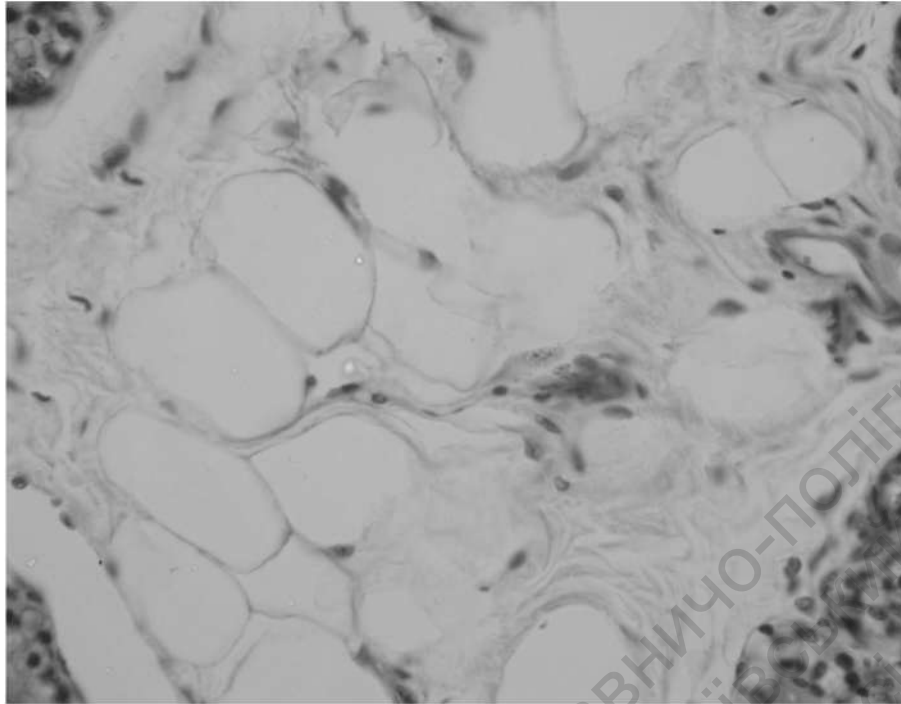


**Specimen 2. Reticular tissue, lymph node**  
(silver impregnation,  $\times 400$ ):

1) reticular fiber.

## Topic 6

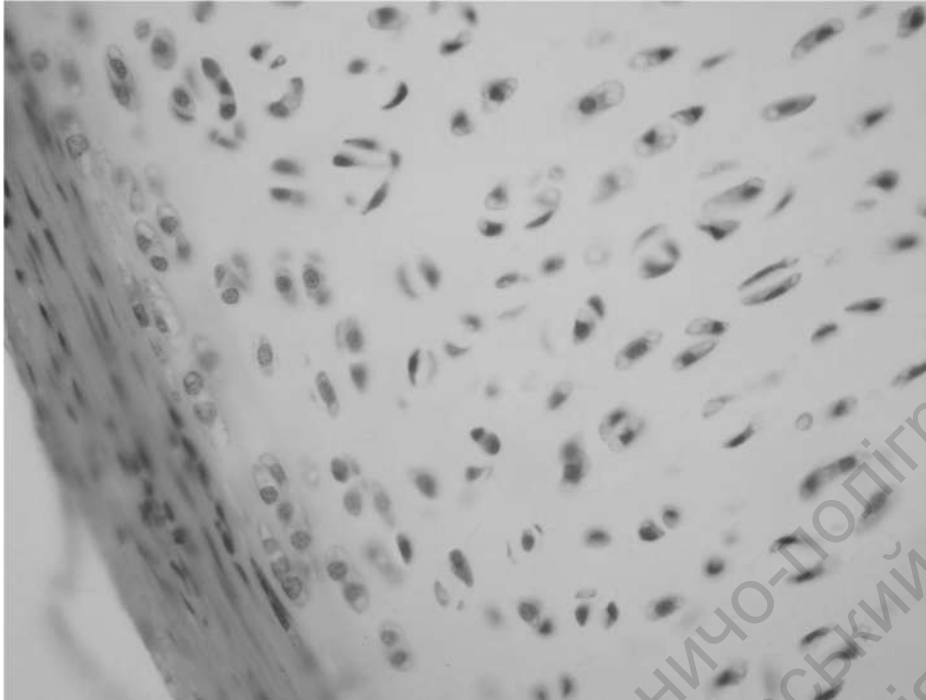# SPECIALIZED CONNECTIVE TISSUE



**Specimen 3. Adipose tissue (hematoxylin and eosin stain, ×400):**  
1) adipocytes; 2) nucleus; 3) lipid droplet.

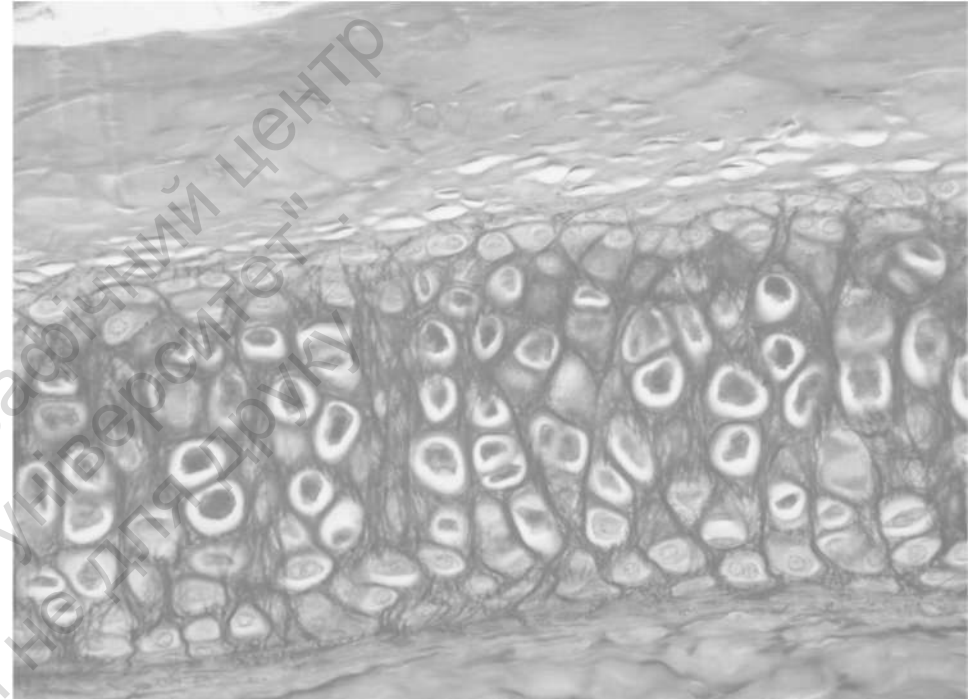
Teacher's signature \_\_\_\_\_

## Topic 7 CARTILAGE



**Specimen 1. Hyaline cartilage  
(hematoxylin and eosin stain, ×400):**

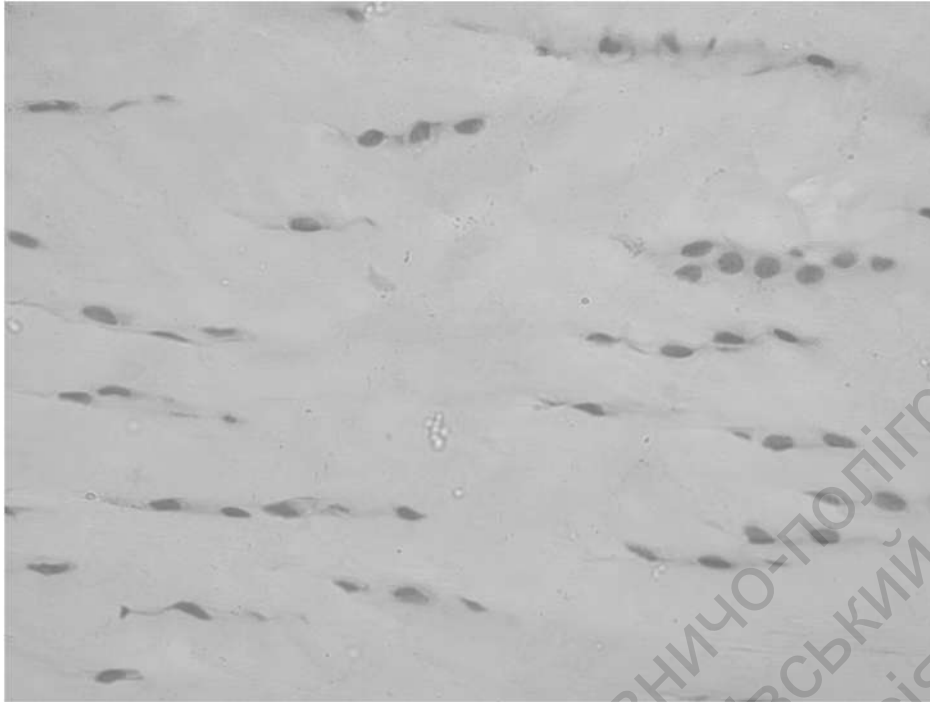
- 1) perichondrium;
- 2) chondroblast;
- 3) chondrocyte;
- 4) isogenous cell group;
- 5) amorphous ground substance.



**Specimen 2. Elastic cartilage  
(orcein stain, ×400):**

- 1) perichondrium,
- 2) chondroblast,
- 3) chondrocyte;
- 4) heterogeneous matrix with elastic fibers.

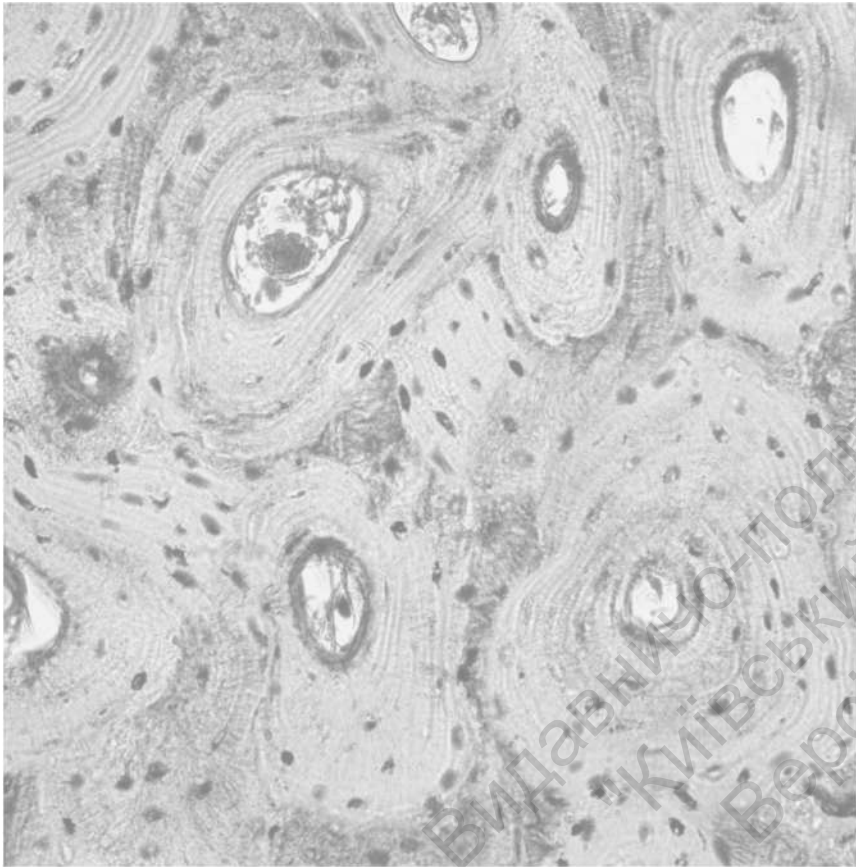
## Topic 7 CARTILAGE



**Specimen 3. Fibrocartilage (hematoxylin and eosin stain, ×400):**  
1) chondrocyte; 2) fibrocyte; 3) collagen fibers.

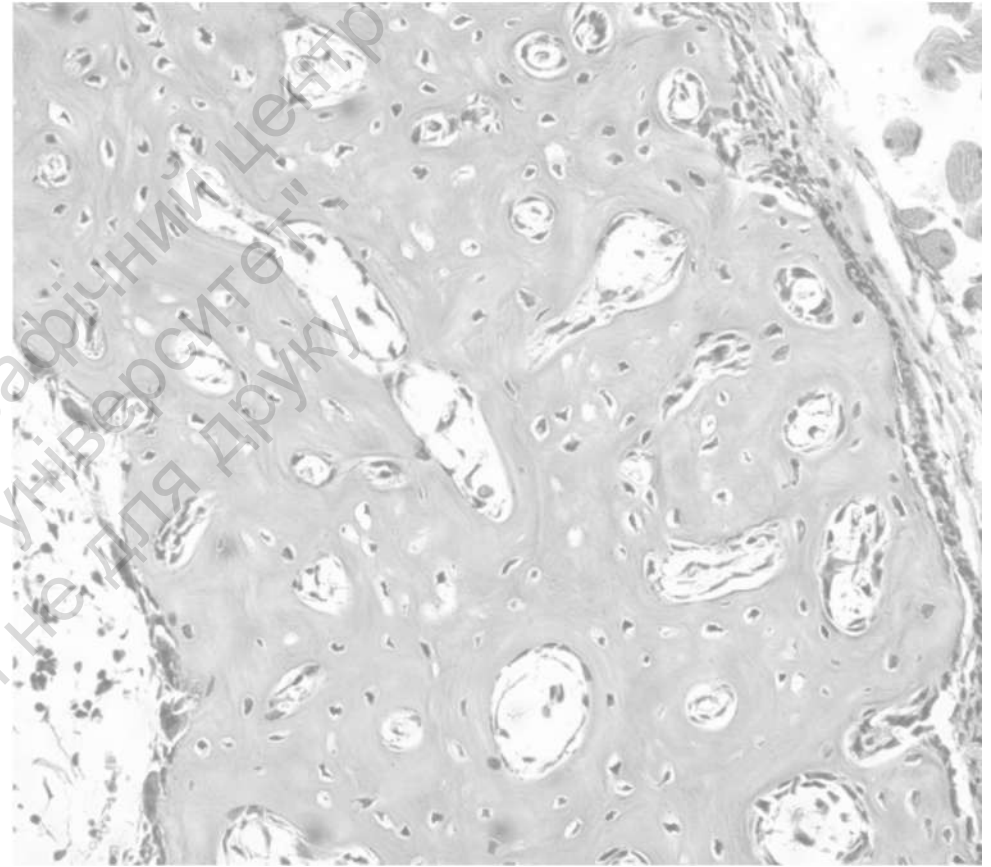
Teacher's signature \_\_\_\_\_

## Topic 8 BONE



**Specimen 1. Dense bone, cross (transverse) section  
(Schmorl stain: tironin and picric acid;  $\times 400$ ):**

1) osteon; 2) canal of osteon; 3) osteocyte; 4) canaliculi; 5) lamella.

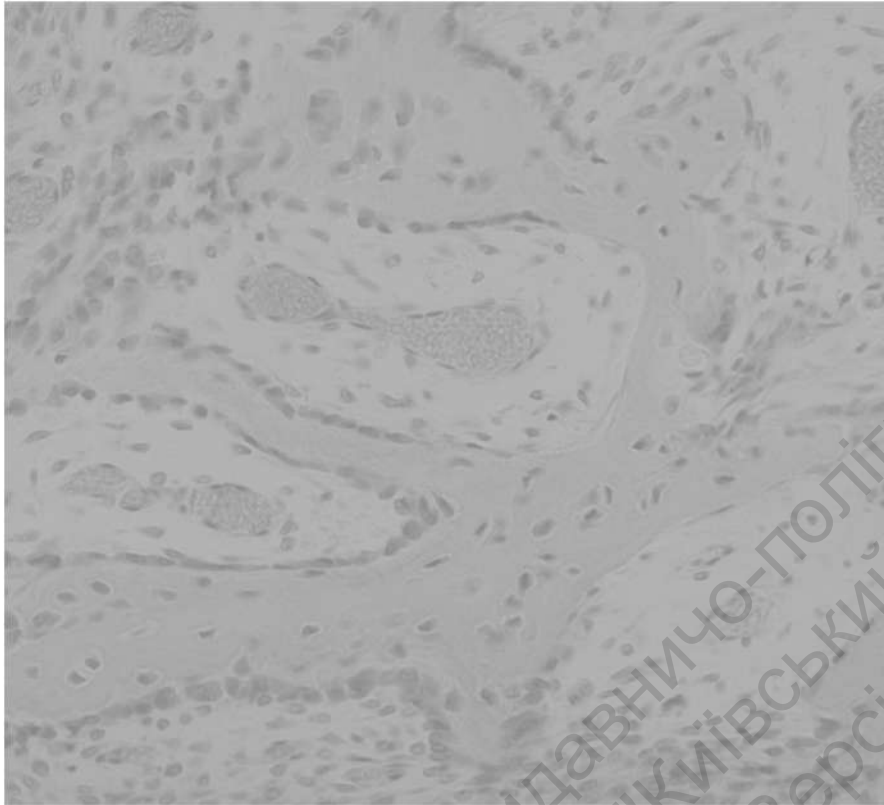

**Specimen 2. Dense bone, cross section  
(hematoxylin and eosin stain,  $\times 100$ ):**

1) periosteum; 2) external lamella; 3) osteon; 4) osteocytes;  
5) canal of osteon.

## Topic 9

# BONE DEVELOPMENT



**Specimen 1. Bone development within mesenchymal (hematoxylin and eosin stain, ×400):**

- 1) bone matrix (woven bone);
- 2) osteoblast;
- 3) osteocysts;
- 4) osteoclast;
- 5) mesenchyme.




**Specimen 2. Bone development within cartilage model, cross section (hematoxylin and eosin stain, ×400):**

- Epiphyseal plate cartilage: 1) resting zone; 2) proliferative zone; 3) hypertrophic cartilage zone; 4) calcified cartilage zone; 5) zone of resorption.

**Teacher's signature** \_\_\_\_\_

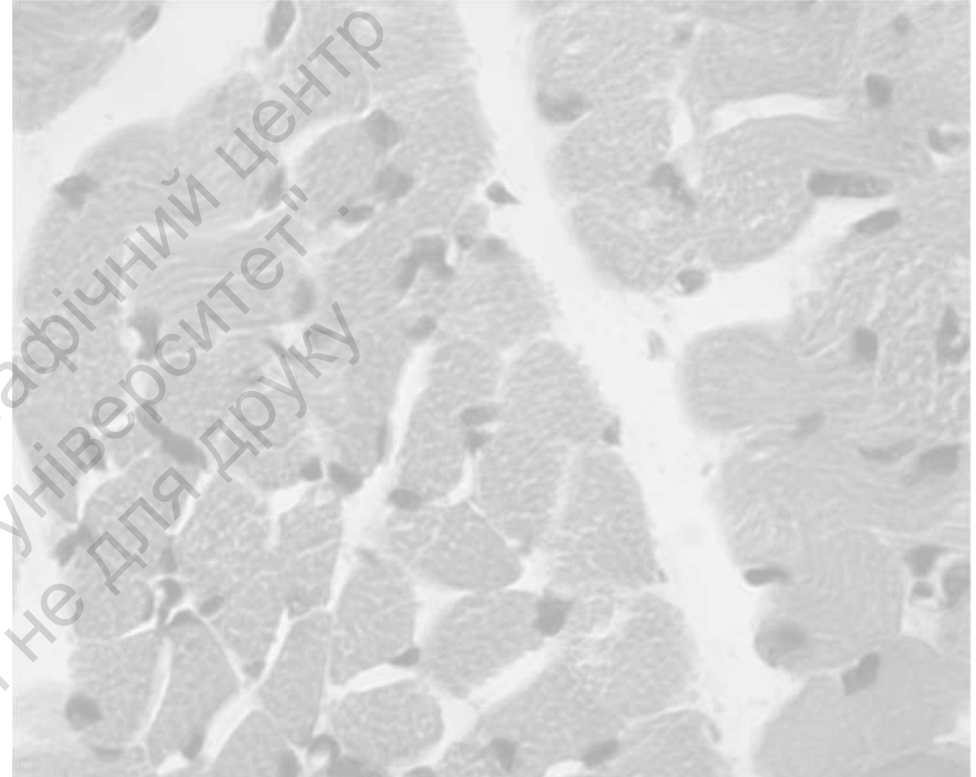
## Topic 10

# MUSCLE TISSUE



**Specimen 1. Skeletal muscle tissue, longitudinal section  
(iron hematoxylin stain, ×400):**

1) skeletal muscle fiber; 2) nucleus; 3) cytoplasm of skeletal muscle cell (sarcoplasm); 4) plasma membrane of skeletal muscle cell (sarcolemma); 5) dark band of sarcomere; 6) light band of sarcomere.



**Specimen 2. Skeletal muscle tissue, cross (transverse) section  
(hematoxylin and eosin stain, ×400):**

1) skeletal muscle fiber; 2) nucleus;  
3) cytoplasm of skeletal muscle cell (sarcoplasm);  
4) plasma membrane of skeletal muscle cell (sarcolemma).

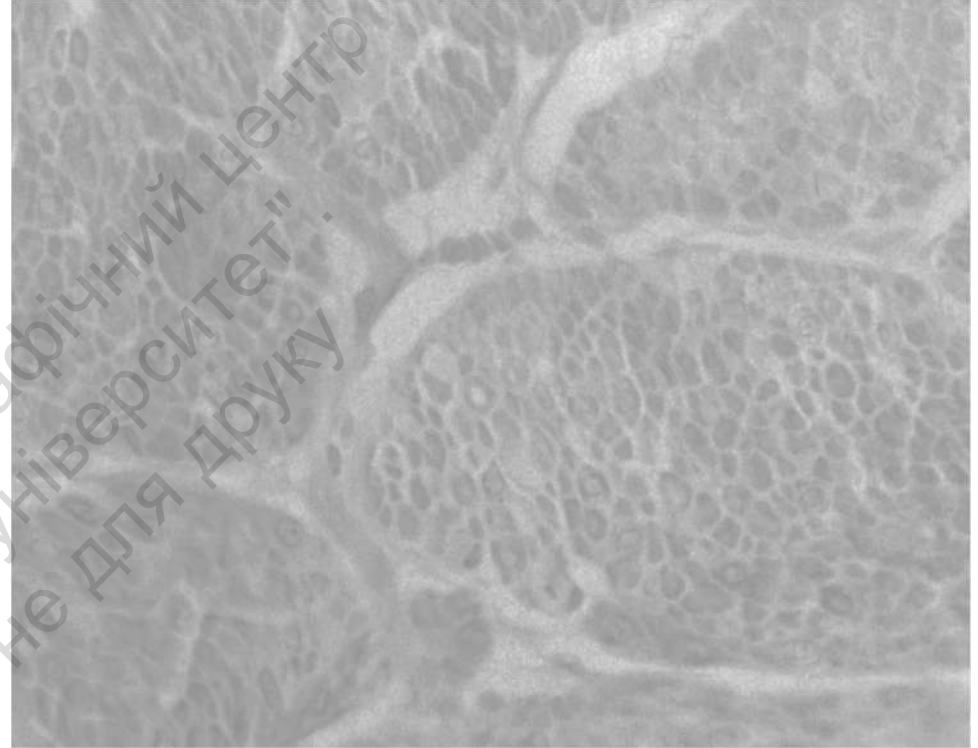## Topic 10

# MUSCLE TISSUE



**Specimen 3. Smooth muscle tissue, longitudinal section  
(hematoxylin and eosin stain, ×400):**

- 1) smooth muscle cell;
- 2) nucleus of smooth muscle cell;
- 3) cytoplasm of smooth muscle cell.



**Specimen 4. Smooth muscle tissue, cross (transverse) section  
(hematoxylin and eosin stain, ×400):**

- 1) smooth muscle cell;
- 2) nucleus of smooth muscle cell;
- 3) cytoplasm of smooth muscle cell.

## Topic 10 MUSCLE TISSUE



**Specimen 5. Cardiac muscle, longitudinal section  
(iron hematoxylin stain, ×400):**

- 1) cardiomyocyte (cardiac muscle cell);
- 2) nucleus of cardiomyocytes;
- 3) intercalated disc;
- 4) anastomosis between cardiomyocytes.

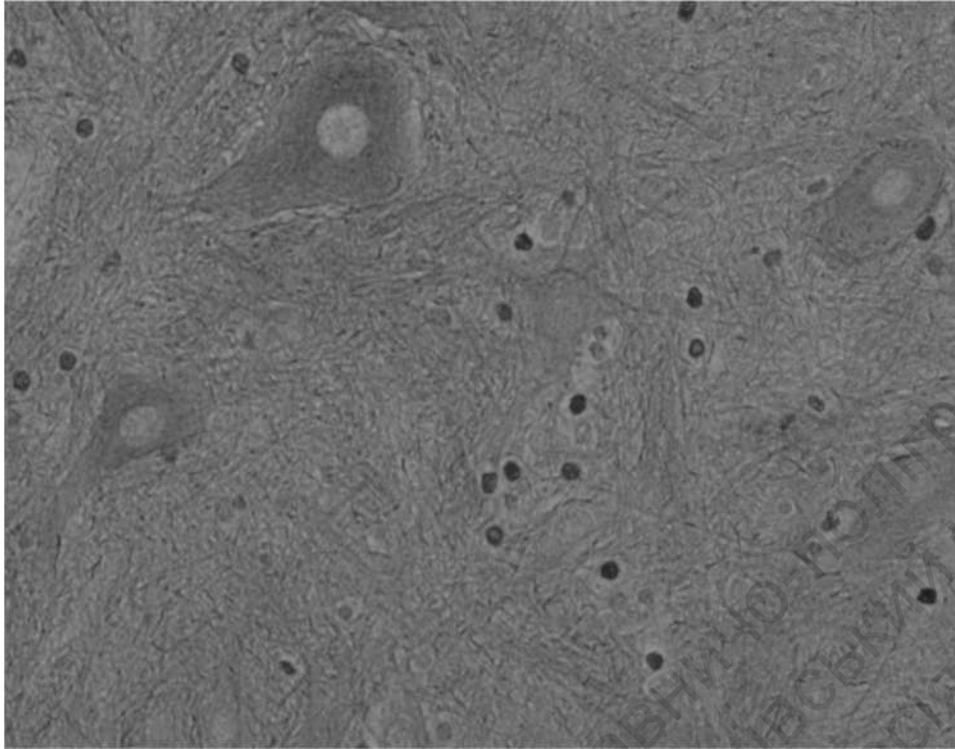


**Specimen 6. Electron microscope image of striated muscle tissue**

- 1) sarcomere;
- 2) Z-line;
- 3) I-band (actin filaments);
- 4) A-band (zone of overlapping);
- 5) H-band (myosin filaments);
- 6) M-line;
- 7) mitochondria;
- 8) terminal cisternae of sarcoplasmic reticulum.

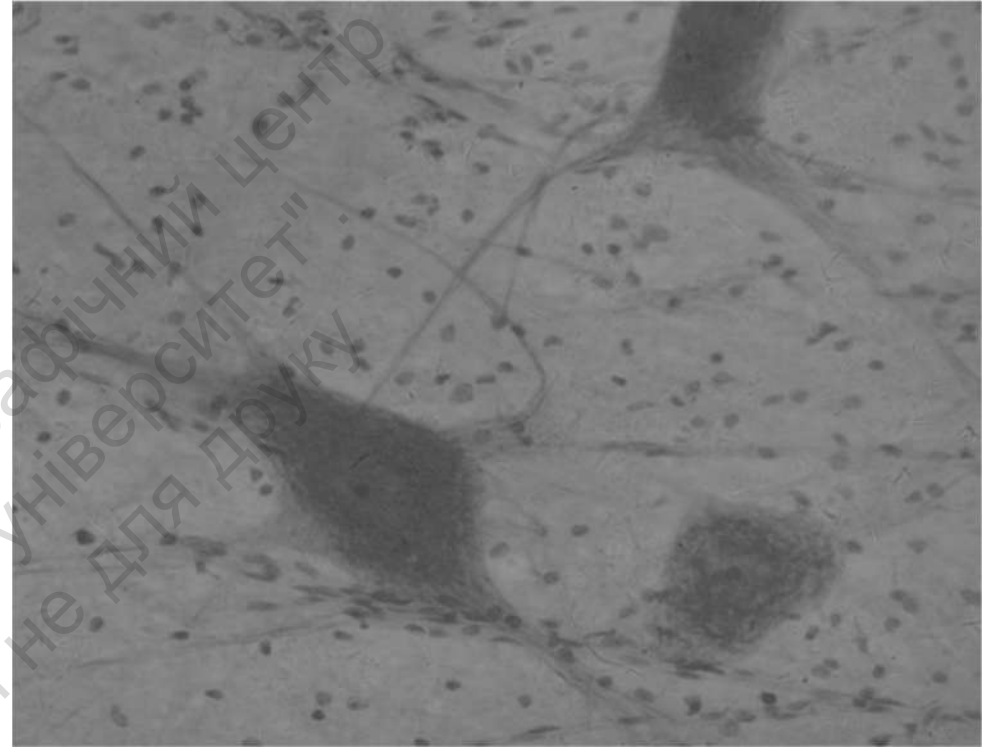
Teacher's signature \_\_\_\_\_

## Topic 11 NERVE TISSUE



**Specimen 1. Motor neurons in spinal cord  
(silver impregnation, ×400):**

- 1) soma (perikaryon) of nerve cell; 2) intermediate filaments (neurofibrils);  
3) nucleus of nerve cell; 4) nucleolus of nerve cell.



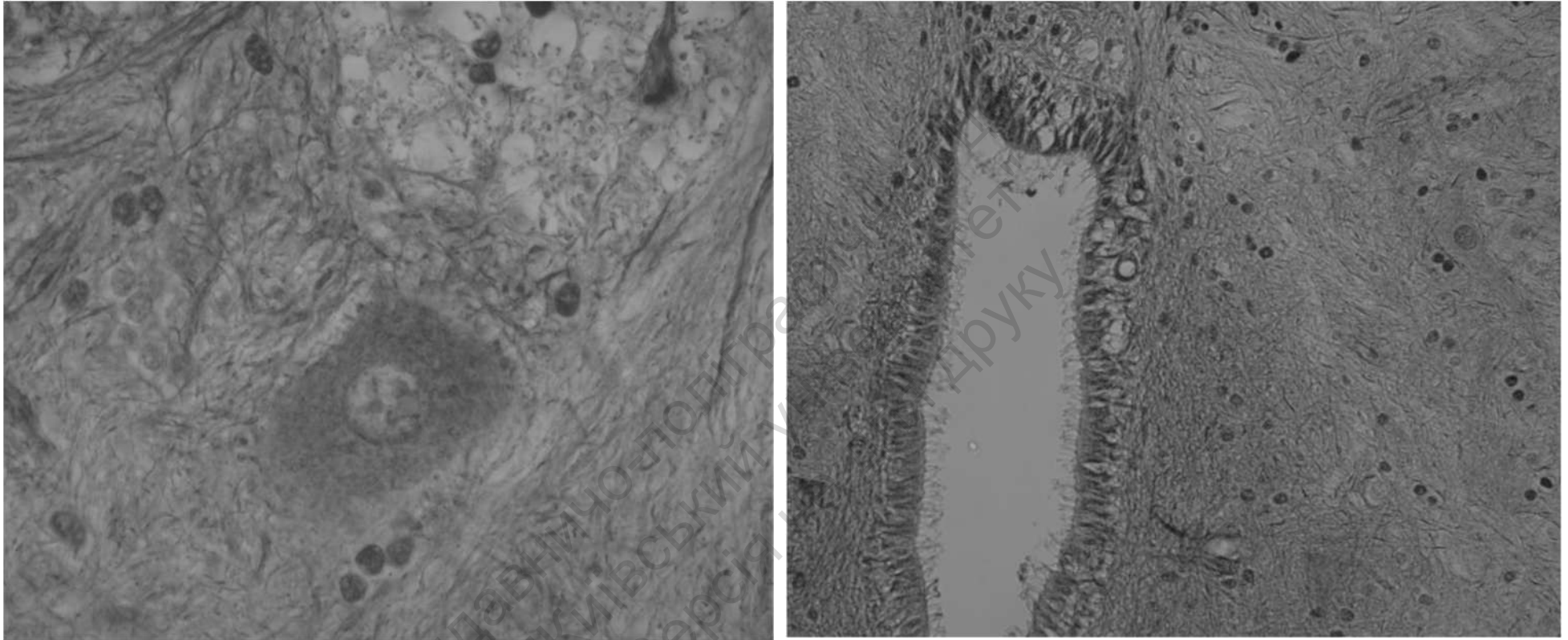
**Specimen 2. Nerve cells (methylene blue stain, ×400):**

- 1) soma (perikaryon) of nerve cell; 2) Nissl bodies; 3) axon hillock;  
4) nucleus; 5) nucleolus.

**Teacher's signature** \_\_\_\_\_

## Topic 12

# NERVE TISSUE, GLIAL CELLS



**Specimen 1. Spinal cord (silver impregnation, ×400):**

### **Glial cells in gray matter**

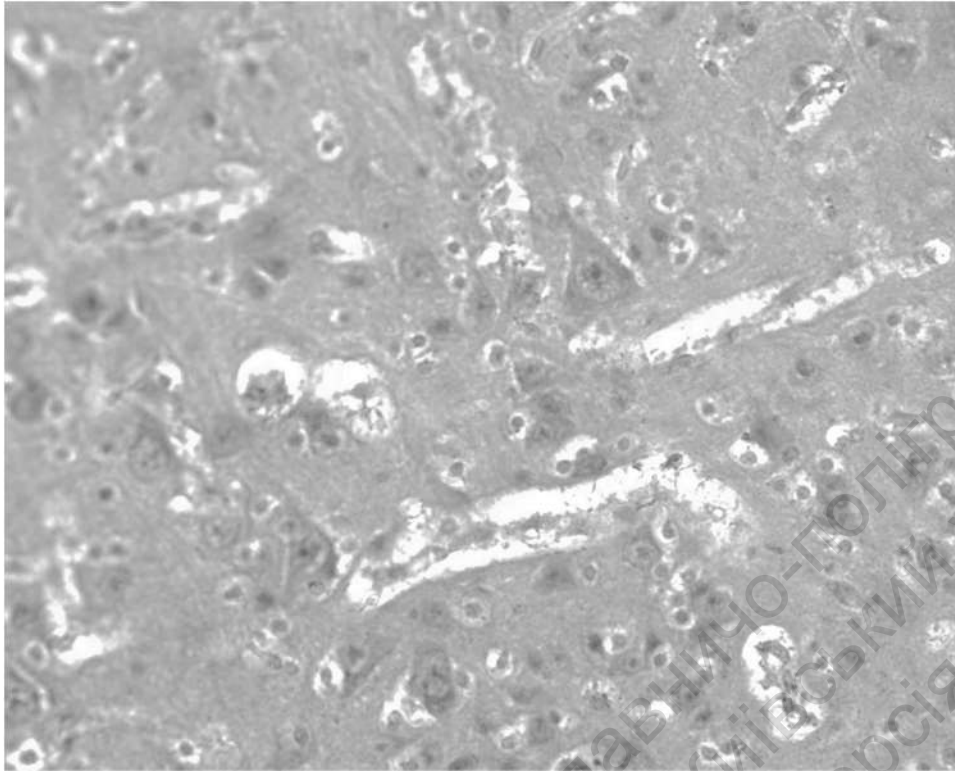
1) nucleus of astrocyte; 2) nucleus of oligodendrocyte; 3) nerve cell.

### **Central canal**

1) ependymal cells, 2) cilia.

## Topic 12

### NERVE TISSUE, GLIAL CELLS




**Specimen 2. Nerve cells and glial cells in cerebral cortex  
(hematoxylin and eosin stain,  $\times 400$ ):**

- 1) nucleus of oligodendrocyte; 2) nucleus of astrocyte;
- 3) nucleus of pyramidal neuron.

Teacher's signature \_\_\_\_\_

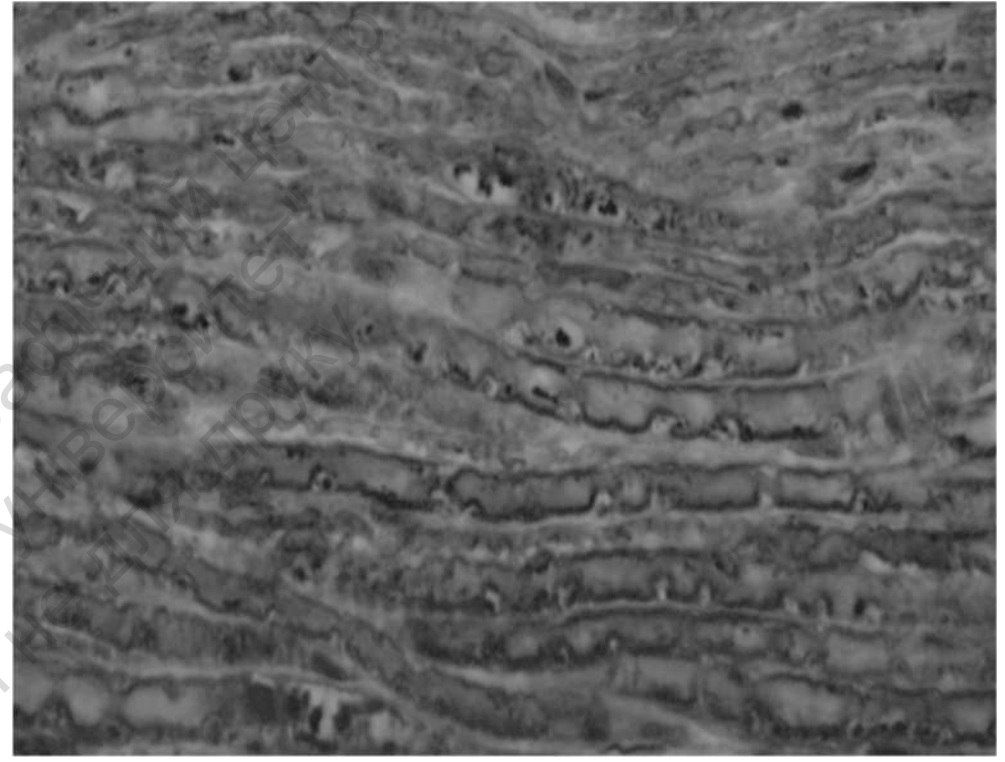
## Topic 13

# NERVE TISSUE



**Specimen 1. Myelinated nerve fibers**  
**(osmium tetroxide stain, ×400):**

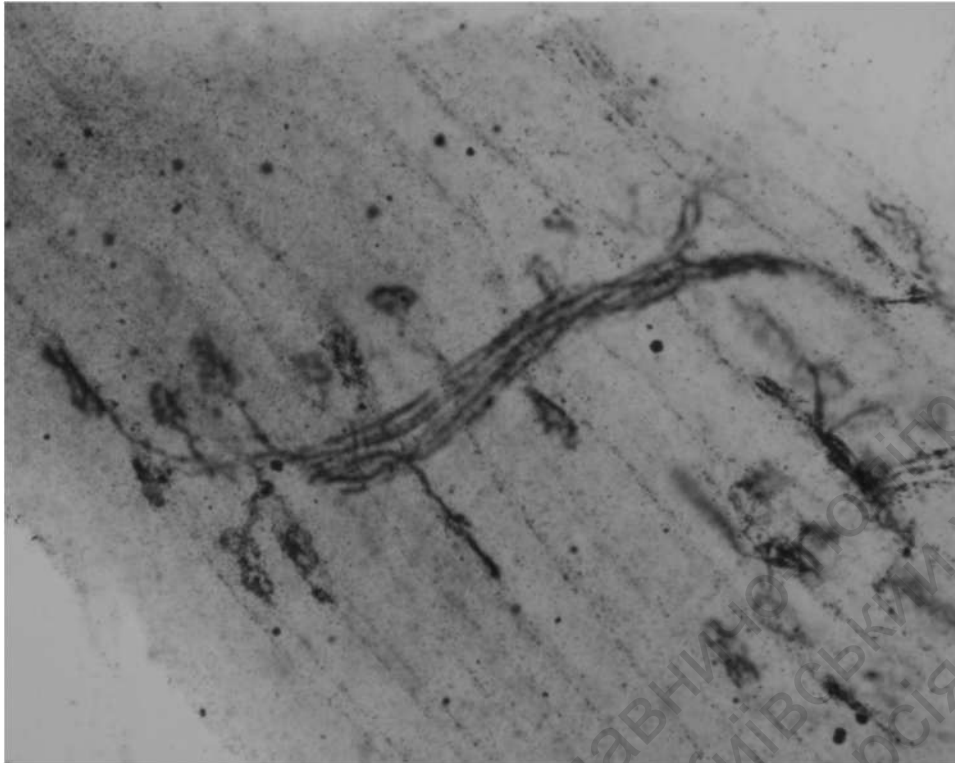
1) axon; 2) myelin sheath; 3) node of Ranvier; 4) Schmidt-Lanterman cleft.



**Specimen 2. Myelinated nerve fibers**  
**(hematoxylin and eosin stain, ×400):**

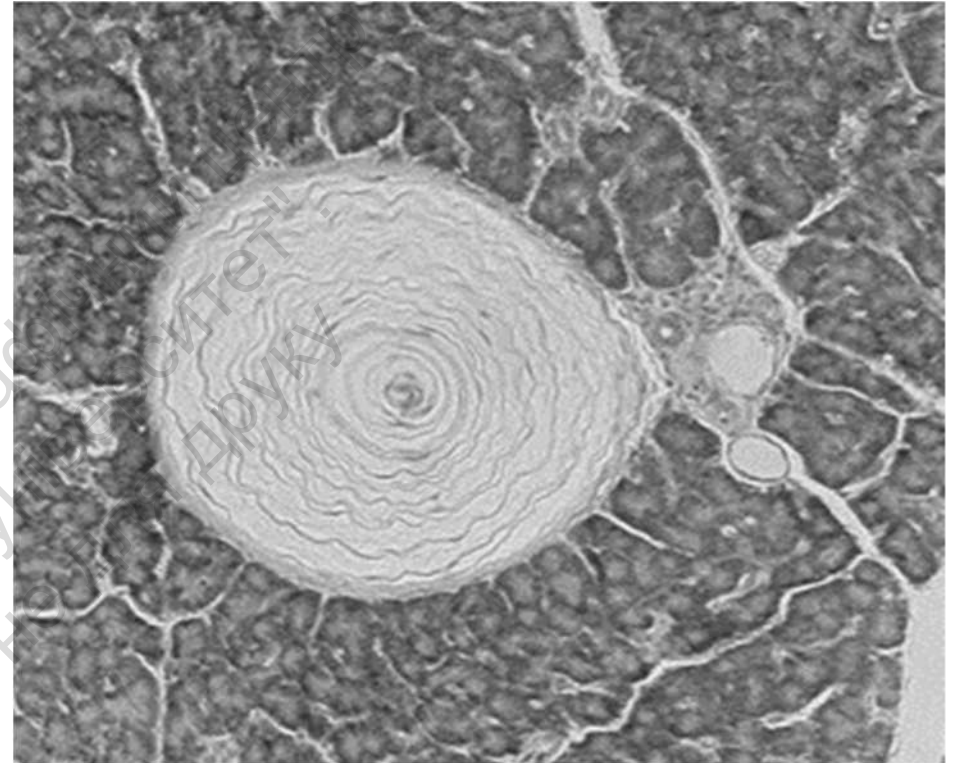
1) axon; 2) myelin sheath; 3) node of Ranvier; 4) Schmidt-Lanterman cleft.

## Topic 13 NERVE TISSUE



**Specimen 3. Nerve ending in muscle (effector)**  
**(silver impregnation and eosin stain, ×400):**

1) nerve ending; 2) muscular fiber; 3) motor end-plates.



**Specimen 4. Pacinian corpuscle**  
**(hematoxylin and eosin stain, ×150):**

1) nerve ending (encapsulated); 2) pancreatic acini; 3) pancreatic ducts.

**Teacher's signature** \_\_\_\_\_